

A Ten Year Review of Verrucae: a Hospital-Based Study in South-South, Nigeria

*Imasogie DE,¹ Olu-Eddo AN,¹ Azeke AT²

ABSTRACT

Verrucae are benign contagious epithelial tumours caused by human papilloma viruses (HPV). They can cause cosmetic concerns and stigmatization on one hand while on the other hand, they have the rare potential to transform into a malignant lesion. Despite this, there exists a dearth of data of their exact frequency in our environment in particular and in Nigeria in general. The aim of this study therefore, was to determine the frequency, age and sex distribution of the verrucae at the University of Benin Teaching Hospital, Benin City, Edo State. This was a descriptive cross-sectional retrospective study of all cases of Verrucae diagnosed histologically between 1st of January 2004 to 31st of December, 2013. The data obtained from this study was analysed using descriptive statistics (i.e. measures of frequency [counts, percent and frequency], measures of central tendency [mean and median] and measures of variations [range and standard deviations]). Forty-one cases of Verrucae were seen during the 10 year study period. Sixteen of these cases occurred in males while 25 occurred in females giving a male to female ratio of 1:1.6. The mean age for Verrucae was 37.63 years (SD = 19.62). The most common variant was the Verruca vulgaris. There was no case of malignant transformation. Verrucae exist in our environment affecting more of the teenage and young age groups with preponderance in females.

Keywords: *Verrucae, verruca vulgaris, verruca plana, verruca plantaris, condyloma acuminatum*

INTRODUCTION

Verrucae (viral warts) are common lesions that occur in the skin and sometimes in the mucous membrane.^{1,2} The human papillomaviruses (HPV) are the causative organism of this lesion.^{1,3,4} Their transmission is either by direct or indirect contact.¹ Their treatment may be challenging, however, they are known to resolve spontaneously or have the potential for malignant transformation when infected with some high-risk HPV subtypes including types 6, 11, 16, 18, 31, and 35.^{1,5} Skin diseases including but not limited to Verruca and their complications are a noteworthy source of health burden in many countries of the world.⁶ Although viral warts are common, there is paucity of data as to their exact frequency.⁷ Similarly, there is paucity of data as to the frequency, age and sex distribution of verrucae in our own environment in particular and in Nigeria in

general. This study aims to determine the frequencies, age and sex distribution of the verrucae at the University of Benin Teaching Hospital, Benin City, Edo State, South Southern Nigeria.

MATERIALS AND METHODS

This was a descriptive cross-sectional retrospective study. The targets of this study were all cases of Verrucae diagnosed histologically between January 2004 and December 2013 in the Department of Anatomic Pathology, University of Benin Teaching Hospital. The Department of Anatomic Pathology receives skin biopsies from Dermatology and General Surgery Departments in University of Benin Teaching Hospital, Secondary and Primary Health Care Centres within the Benin City metropolis, neighbouring towns and villages in Edo State, as well as neighbouring states. The surgical pathology register, histology request form and duplicate copies of the histology report were useful in providing information on the age, sex, nature of specimen, hospital number, histology laboratory number, clinical presentation and clinical diagnosis of each

Department of Anatomic Pathology,¹ University of Benin Teaching Hospital, Benin City, Nigeria.

Department of Anatomic Pathology,² Irrua Specialist Teaching Hospital, Irrua, Nigeria.

*Corresponding author: eradebamwen4real@yahoo.com

Date manuscript was received: 18/1/2021

Date manuscript was accepted: 7/3/2021

patient/case. Histology slides were retrieved, reviewed under the light microscope and the diagnosis recorded against the corresponding patient's name on a data spreadsheet. Newly prepared sections were made from the paraffin-embedded tissue blocks that were retrieved from the archives of the Department of Anatomic Pathology, University of Benin Teaching Hospital and stained with haematoxylin and eosin in cases where slides were missing or the quality of the slide had greatly diminished.

The data obtained from this study were analysed using descriptive statistics. For categorical variables (sex and histologic diagnosis of verrucae), the measures of frequency (i.e. count, percent and frequency) while for continuous variables, the measures of central tendency (i.e. mean and median) and measures of dispersion (range and standard deviation) were analysed.

RESULTS

Of the 375 cases of skin tumours seen during the 10 years study period, 188 cases were benign in their course. Verrucae accounted for 41 cases which represented

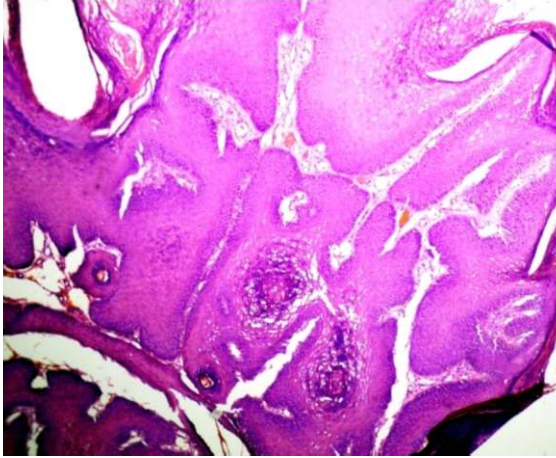
10.9% and 21.81% of all skin tumours and benign skin tumours respectively. Of the 41 cases, 16 cases occurred in males, while 25 cases occurred in females giving a male to female ratio of 1:1.6.

Table 1, shows the age and sex distribution of the study population. The mean age for Verrucae was 37.63 years (SD = 19.62) with an age range of 10-84 years and a peak in the 3rd decade. The mean ages for Verrucae in males and females were 39.86 years (SD = 19.17) and 36.20 years (SD = 20.15) respectively. The anatomic site of the specimen was specified in only 17 cases, with 5 cases each in the head/neck and trunk while the lower limbs anogenital region and upper limb accounted for 4 cases, 2 cases and a case respectively.

Verruca vulgaris was by far the major subtype of Verruca observed in this study. It was present in 37 cases (90%). Condylomata acuminata accounted for 2 cases while Verruca plana and Verruca plantaris each accounted for a case. Figures 1-4 show photomicrographs of different types of Verrucae.

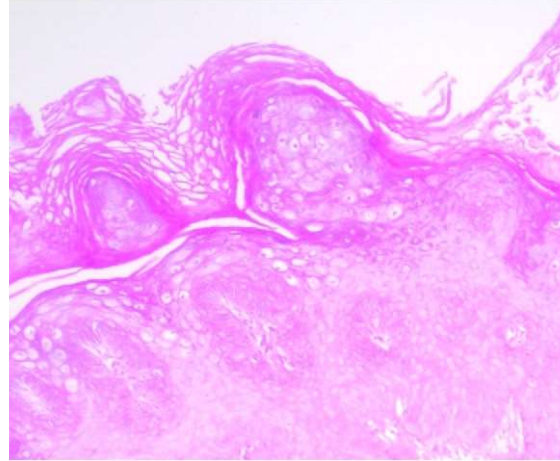
Table 1: Showing the age and sex distribution of verrucae

Age group	Verruca vulgaris		Condyloma acuminatum		Verruca plana		Verruca palmaris		Total
	Male	Female	Male	Female	Male	Female	Male	Female	
10-19	1	3	0	0	0	0	0	0	4
20-29	4	8	0	1	0	0	0	1	14
30-39	5	1	1	0	0	0	0	0	7
40-49	2	4	0	0	0	0	0	0	6
50-59	1	2	0	0	0	0	0	0	3
60-69	1	2	0	0	0	0	0	0	3
70-79	1	0	0	0	0	0	0	0	1
80-89	1	1	0	0	0	1	0	0	3
Total	16	21	1	1	0	1	0	1	41



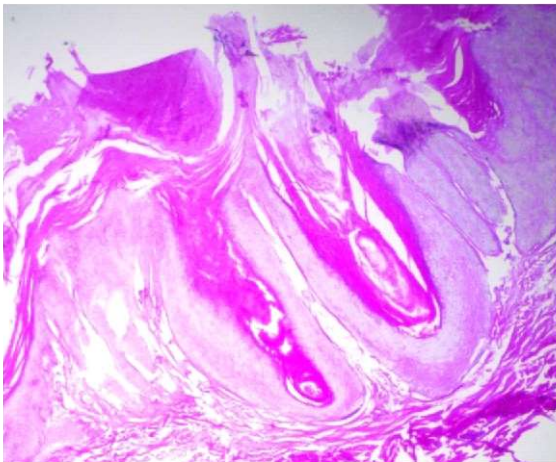
H and E x 40

Figure 1: Verruca vulgaris showing hyperkeratosis, parakeratosis, thickened granular layer, papillomatosis and acanthosis.



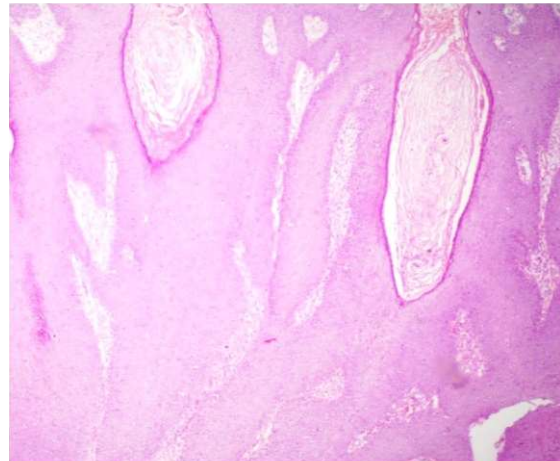
H and E x 100

Figure 2: Verruca plana showing basket-weave hyperkeratosis, acanthosis with paucity of parakeratosis and papillomatosis and numerous vacuolated cells are seen in the upper part of the epidermis including the granular layer.



H and E x 40

Figure 3: Verruca plantaris showing hyperkeratosis and invagination of the acanthotic epidermis.



H and E stain. x 40

Figure 4: Condyloma acuminatum showing hyperkeratosis, papillomatosis and acanthosis.

DISCUSSION

Verrucae are benign lesions that occur in the skin but it has also been reported to occur in the mucous membranes.^{1,8} This lesion is a common contagious epithelial tumour caused by human papilloma viruses (HPV).³ This infective viral organism is a double-stranded DNA virus that has more than 100 genotypically different forms, however, only some of them have been implicated as the cause of Verrucae.^{1,9}

Infection with HPV leads to clonal proliferation at the basal layer of the epidermis with associated acanthosis and hyperkeratosis

resulting in the development of warty growth (Verruca).¹⁰ For this to occur, HPV gains primary access to the cells of the basal layer of the epidermis through minor abrasions that may have resulted from trauma, scratching, biting or sucking of the finger nails.^{11,12} Trauma, shaving and scratching can predispose an individual with the primary lesion to develop the lesion in secondary sites through autoinoculation.¹¹ Immunosuppression plays a role in the progression of the disease.⁴ The majority of Verrucae do not

cause symptoms however they can cause cosmetic defacement and stigmatization especially when it is generalized thus affecting the patient's quality of life.^{1,4,13}

Kilkenny *et al.* noted that there was paucity of data as to the exact frequency of Verrucae.⁷ This observation has perhaps limited the acquisition of comparative data concerning this lesion. Verrucae accounted for approximately 1/5th (21.81%) and 1/10th (10.9%) of benign skin tumours and all skin tumours respectively in this study. A lower percentage of 0.7 to 7.3% of Verrucae had been reported from previous studies.¹⁴⁻¹⁹ The diagnosis of Verrucae from these studies were mainly from clinical impression with non or occasional histopathological diagnoses.¹⁴⁻¹⁹ These may have contributed to a lower percentage of Verrucae in these previous studies in comparison to our own study that employed histopathological diagnosis. Another factor that may account for this lower percentage of Verrucae in these previous studies may be related to their study design. While these previous studies calculated the frequency of Verrucae from skin diseases presenting at the dermatology clinic,¹⁴⁻¹⁹ our own study looked at this lesion from the specimen submitted for histopathologic analysis and diagnosis. The latter is more likely to be specific in the diagnosis of the lesion more so that histopathological study is considered the gold standard for diagnosis of skin diseases.²⁰ The practice of dermatology therefore requires skin biopsy for histology as a common procedure.²¹ A high clinico-pathological discordance between the clinical and pathological diagnoses of skin disease has been reported by previous studies, thus giving credence to the latter as the gold standard for the diagnosis of skin diseases.^{22,23}

Teenage persons and young adults are the main sufferers of cutaneous warts.⁴ This is consistent with the findings of this study where approximately 60% (25/41) of the study population fell within teenage and young adult age groups. This finding is strengthened by a peak incidence in the 3rd decade as noticed in this study.

A female preponderance was noted in this study. This observation is contrary to what had been documented in Caucasians.³ In Caucasians, both sexes had been documented by the World Health Organization to be equally affected.³

Verruca vulgaris is the most common type of viral warts (Verrucae).²⁴ This is consistent with the observation of this study. Malignant transformation can occur especially in genital warts (Condyloma acuminatum), the elderly and the immunocompromised patient.^{1,2} No malignant transformation was noted in this study.

A limitation of this study is the paucity of similar work in our environment in particular and other parts of the country in general. This has reduced the depth of discussion with respect to the findings of this study vis-à-vis comparison with other studies of a similar nature.

CONCLUSION

Verrucae are present in our environment, although the paucity of data as to their exact frequency has limited discussion in this respect. The Verruca vulgaris was by far the most common subtype while the teenage and young adults accounted for most cases. Females were more affected with this lesion while no case of malignant transformation was recorded.

REFERENCES

1. AlAboud AM, Nigam PK. Wart. Available at: <https://www.ncbi.nlm.nih.gov/books/NBK431047/>. Last accessed on 20th April, 2021.
2. Billings SD. 'Dermatosis': In: Goldblum RJ, Mckenney JK, Lamps LW, Myers JL (eds). Rosai and Ackerman's Surgical Pathology. Philadelphia, Elsevier 2017. pp 6-143.
3. LeBoit PE, Burg G, Weedon D, Sarasin A, editors. World Health Organization Classification of Tumours. Pathology and Genetics of Skin Tumours. IARC Press, Lyon: 2006. pp 121-63.

4. Paul HK, Akhtar N, Zakaria ASM, Biswas S. Generalized Verruca Vulgaris A case reports. *Community Med Coll J* 2017;6:29-32.
5. Gladsjo JA, Alió Sáenz AB, Bergman J, Kricorian G, Cunningham BB. 5% 5-Fluorouracil Cream for Treatment of Verruca Vulgaris in Children. *Pediatric Dermatology* 2009;26: 279-85.
6. Atraide DD, Akpa MR, George IO. The pattern of skin disorders in a Nigerian tertiary hospital. *J Public Health Epidemiol* 2011;3:177-81.
7. Kilkenny M, Merlin K, Young R, Marks R. The prevalence of common skin conditions in Australian school students: Common, plane and plantar viral warts. *Br J Dermatol* 1998;138:840-5.
8. Ural A, Arslan Su, Ersoz Å, DeÄÿer Bl. Verruca vulgaris of the tongue: a case report with a literature review. *Bosn J Basic Med Sci* 2014;14:136-8.
9. Harper DM, Franco EL, Wheeler CM, Moscicki AB, Romanowski B, Roteli-Martins CM, *et al.* Sustained efficacy up to 4.5 years of bivalent L1 virus-like particle vaccine against human papillomavirus types 16 and 18: Follow-up from a randomised control trial. *Lancet* 2006;367: 1247-55.
10. Sterling JC, Gibbs S, Hussain SSH, Mustapha MFM, Handfield-Jones S. British Association of Dermatologist's guidelines for the management of cutaneous warts - 2014. *British Journal of Dermatology* 2014;171:696-712.
11. Stulberg DL, Hutchinson AG. Molluscum contagiosum and warts *Am Fam Physician* 2003;67: 1233-40.
12. Theng TSC, Goh BK, Chong WS, Chan YC, Giam YC. Viral warts in children seen at a tertiary referral centre. *Ann Acad Med Singapore* 2004;33: 53-6.
13. Ergun SS, Buyukbabany N. Giant Verruca Vulgaris *Dermatologic Surgery* 2004;30:459-62.
14. Hartshorne ST. Dermatological disorders in Johannesburg, South Africa. *Clinical and Experimental Dermatology* 2003;28:661-5.
15. Mitchell JC. Proportionate distribution of skin diseases in a dermatological practice: enumeration by standard nomenclature of 12,578 cases from clinic and private practice. *Canadian Medical Association Journal* 1967;97:1346-50.
16. Nnoruka EN. Skin diseases in south-east Nigeria: A current perspective. *International Journal of Dermatology* 2005;44:29-33.
17. Ogunbiyi AO, Daramola OOM, Alese OO. Prevalence of skin diseases in Ibadan, Nigeria. *International Journal of Dermatology* 2004;43:31-6.
18. Ukonu AB, Eze EU. Pattern of skin disease at the university of Benin teaching hospital, Benin city, Edo state, South-South Nigeria : a 12 month prospective study. *Glob J Health Sci* 2012;4:148-57.
19. Yahya H. Change in pattern of skin disease in Kaduna, north-central Nigeria. *International Journal of Dermatology* 2007;46:936-43.
20. Werner B. Skin biopsy and its histopathologic analysis: Why ? What for ? How ? Part I. *An Bras Dermatol* 2009;84:391-5.
21. Werner B. Skin biopsy with histopathologic analysis: Why ? What for ? How ? Part II *An Bras Dermatol* 2009;5:507-13.
22. Gonzalez L, Di Martino B, Rodriguez M, Knopfmacher O, Bolla L, *et al.* Clinical and epidemiological study of adnexal Tumours at the Dermatology Department of the Medical Sciences Faculty, National University of Asuncion.Paraguay, 2002-2008. *Folia Dermatol* 2009;20:135-9.
23. Samaila MOA. Adnexal Skin Tumors in Zaria, Nigeria. *Ann Afri Med.* 2008; 7 : 6 - 8 . Available from : <http://www.annsafrmed.org/text.asp?2008/7/1/6/55691>. Accessed on 12/10/2012.
24. Murphy GE, Sellheyer K, Mihm MC. Skin. In Kumar V, Abbas AB, Fausto F, eds. *Robbins and Kotran Pathologic Basis of Disease*. Philadelphia, Saunders 2005. pp 1227-73.